

CANINUL MAXILAR INCLUS-STUDIUL RADIOLOGIC OBSERVAȚIONAL ASUPRA FRECVENȚEI

The Impacted Upper Canine- An observational radiological study upon the frequency

Anca Stefania Mesaros¹, Alexandrina Muntean¹, Jerome Prunier¹,
Cristina Borzan², Roxana Oancea³, Meda Simu¹,

¹Faculty of Dentistry, Iuliu Hațieganu University of Medicine and Pharmacy Cluj-Napoca

²Faculty of Medicine, Iuliu Hațieganu University of Medicine and Pharmacy Cluj-Napoca

³Faculty of Dentistry, University of Medicine and Pharmacy Victor Babeș, Timișoara

Correspondent author: Alexandrina Muntean, e-mail:ortoanda@yahoo.com

Abstract:

Tooth impaction is a very frequent anomaly nowadays. Impacted maxillary canines are second most frequent but more addressed than other impactions such as the 3rd molars, because of the importance the canine has from both functional and aesthetical point of view. The present study wishes to address the problematic of the impacted maxillary canines by doing a prevalence study. Panoramic radiographs taken on a period of 3 months in two radiological centers in two different cities in Romania underwent a screening for impacted maxillary canines and the positive diagnosed cases were further assessed.

The results of our study show similar values of prevalence and other clinical aspects with results reported in the international literature. This shows the importance of early diagnosis in the dental office so that adequate follow-up and treatment can be put in place at the best time.

Key-words: *tooth impaction, panoramic x-rays, prevalence, screening*

Introduction:

Impacted teeth are classically defined as teeth retained in the maxilla beyond their normal date of eruption, surrounded by their peri-coronary sac and without communication with the oral cavity [15].

These are teeth whose apical root edification ended before the eruption process allowed them to reach the oral environment. There is no discontinuity of the oral mucosa, therefore there is neither opening nor contamination of the peri-coronary sac by oral bacterial flora. Impaction can be close to the normal environment or elsewhere in the maxilla; it is called ectopic impaction, or can be found elsewhere in the body and is then called heterotopic impaction [5].

In humans, dental eruption is a complex process, regulated by the cellular and tissue elements associated with the evolving dental germ, which allows a tooth to move from its bony germinal site to its functional site on the dental arch.

The germ of the canine has a high position in the maxilla; the crown has usually a mesial and palatal orientation. When the canine migrates down and forward, towards the

occlusal plane, the tooth becomes progressively more vertical until it reaches the distal side of the root of the lateral incisor and the mesial aspect of the apex of the deciduous canine [19].

During its development, the germ moves constantly, modifying its relationship with the surrounding tissues. Once the tooth has reached its functional location, a smaller and slower axial displacement is taking place.

Canine eruption is associated with vestibular bone resorption, in the direction of eruption of the tooth, and palatal or lingual bone apposition at the bottom of the alveoli. The displacement of the tooth is therefore mainly related to an axial eruptive movement, but oblique, lateral and tilting movements can also be observed.

Different hypotheses exist today to explain the mechanisms responsible for the inducing force responsible for the eruption, however, we do not have any indisputable evidence corroborating a unifying hypothesis. Therefore it is considered the eruption as a multifactorial process. For the eruption to occur, 4 processes are needed:

- a mechanism generating forces capable of enabling the egression of the tooth

- a process by which such forces allow the eruption through movements through surrounding tissues
- a process that maintains the eruption so that the tooth is maintained in its new position
- a remodeling of the periodontal tissues to maintain the functional integrity of the system.

The mechanisms that allow the eruption are not yet fully known. It is a set of forces that drive the tooth in the axis from its developmental position to its functional position in the occlusal plane [7].

The role and shape of the canine are related. The canine participates in the section of the alimentary bolus with the incisors and, less noticeably, the crushing of the alimentary bolus with the premolars and molars. Because of its position on the arch and its morphology, it can withstand significant pressures.

The canine has an important role in occlusion and in mandibular kinetics. It allows the disengagement of the posterior teeth in right and left lateral movements, thus protecting the posterior teeth from tangential forces and also provides protection in guiding the closing movements of the mandible [23].

Finally, the canines have a role in facial aesthetics and the phonation [2].

With a frequency of 18%, the inclusion of the maxillary canine is the most common after the third molar and affects about 2% of the population. The percentage differs according to the study population, the incidence of maxillary canines included ranging from 0.8 to 3.3% [18].

The included canines are found in 12.2% of orthodontic patients [22].

The inclusion of the maxillary canine is 20 times more common than the mandibular canine [6].

Inclusion affects women more than men ($F / H = 2.3 / 1$), which corresponds to about 1.17% of the female population and 0.51% of the male population, respectively.

Finally, according to some studies the inclusions are palatal with a percentage of 85% (against 15% for vestibular inclusions) and unilateral at 92% of the cases with canine impaction [22]. Other studies suggest different figures for the position of the included canines, with a palatal position in 50% of cases,

vestibular in 30% of cases and an intermediate position in 20% of cases [4].

The complications encountered by the inclusion of a canine can be:

- lingual or labial malposition of the impacted canine,
- a migration of the neighboring teeth,
- resorption of the root of the adjacent teeth,
- infections that can lead to trismus and pain,
- an increased risk of infection and follicular cystic lesions,
- decrease in the dental arch,
- ankylosis of the included and ectopic canines [19].

One study showed a 7.7% root resorption rate of maxillary lateral incisors adjacent to the canines involved [18]

The diagnosis of an included tooth must be done as soon as possible in order to be able to set up a monitoring of it and a treatment at the most appropriate moment.[20]

The practitioner should suspect an included palatal canine in a patient under 10 years old when there is a family history of included canines, or if the maxillary lateral incisor is abnormal or missing. In patients over 10 years of age the suspicion of canines included occurs when one of the following three phenomena occurs:

- asymmetry to palpation during canine eruption
- the impossibility of canine palpation accompanied by advanced occlusal development
- the distal inclination of the lateral incisor [8]

However, the discovery of an included canine is most often by chance during a screening test or a radiological examination. A preliminary examination of the patient makes it possible to know any genetic predispositions to the inclusions. The symptomatology is not always obvious and requires rigorous examinations.

The inclusion of an maxillary canine can be seen exo-oral by the absence of a correct support of the upper lip.

Radiography validates or invalidates the presence of an included canine suspected after the clinical examination. The use of X-rays also allows the surgeon to choose the best possible treatment and the best access to it during treatment [6].

Several methods can be used for radiological diagnosis; however the panoramic

X-ray provides an overview of dental arches and bone structures. It gives us information about the number of teeth present, the symmetry, the sequence of dental eruption, the presence of pathology, the location and height of the included teeth [6], as well as their axis in the mesio-distal sense.

Panoramic X-ray is considered non-invasive and easy to use. However, it has some flaws. It should be taken into consideration that structures closer to the X-ray source appear larger than those near the detector. The accuracy of the diagnosis using a panoramic X-ray is also reduced by the distortions and overlays that may appear. The evaluation of the accuracy of root resorption is limited, it typically requires three-dimensional information.

Using the occlusal film allows vision in the anteroposterior and transverse direction by placing a large film horizontally in the occlusal plane.

The use of the scanner allows us to obtain three-dimensional images in real size. Data regarding the location and morphology of the impacted teeth with great precision, surrounding structures, anatomical relationships, possible obstacles on their path of eruption, the position of adjacent teeth and the quality of the bone can be obtained.

The age of the patient is a key element in the implementation of preventive treatment. The various preventive therapies are used when a risk of inclusion is detected on a panoramic radiograph or during visual / tactile inspection.

The different treatments that can be put in place by the practitioner consist in the removal of the temporary tooth in order to modify the eruption path of the permanent tooth, which during its evolution will move in the path of least resistance [14]. Extraction of the deciduous tooth, when a permanent canine is diagnosed with a non-compliant eruption path, may improve its trajectory and may sometimes allow the tooth to exit normally. However the success of this technique depends on when the temporary canine is extracted as well as the location of the canine in the maxillary.

It is recommended that the temporary canine be removed when the patient is between 10 and 13 years old, that the permanent canine is not palpable and that a palatal location can be confirmed [11].

Aim:

This study aims to study the prevalence of impacted maxillary canines in a sample of the Romanian population and their characteristics using an assessment of panoramic radiographs of patients taken in two radiological centers. Statistics on the impacted canines according to certain characteristics such as sex and age of the patients, the angulation of the teeth, their location and the attainment of the adjacent teeth is to be interpreted.

Material and Methods:

This study was performed on 792 panoramic radiographs selected at two radiological centers, each in a different city in Romania, respectively Cluj-Napoca and Timișoara, in agreement with the radiological centers.

The inclusion criteria for the study were:

- x-rays were taken between 1st October 2017 and 31st December 2017.
- panoramic X-rays are for patients aged 13 to 26, the age group being defined arbitrarily.
- the selected radiographs had to be of good quality with a ratio of 1:1.

The exact reasons why patients presented themselves to have their panoramic x-rays taken are unknown; they could be for both dental and orthodontic reasons. The databases of the two radiological centers did not contain the reasons of presentation of the patients.

After a thorough examination of each x-ray, it was noted:

- the presence or absence of impacted canines
- the number of impacted maxillary canines
- the quadrant where the impacted canines are located
- the relationship of the impacted canine in report with the midline
- consequences of the canine impaction on the lateral incisors

Of the 792 panoramic x-rays that were studied, 366 were of male patients and 426 female.

Gender	No	%
Male	366	46.20%
Female	426	53.80%
TOTAL	792	100.00%

Table 1-Gender distribution of the population

Distribution of patients according to ages

between 13 and 26 can be observed in the table below.

Age	Male	Female	Total	Total %
13	42	58	100	12.62
14	42	50	92	11.61
15	34	62	96	12.12
16	42	66	108	13.63
17	46	38	84	10.6
18	54	42	96	12.12
19	42	28	70	8.83
20	12	26	38	4.79
21	24	20	44	5.55
22	12	18	30	3.53
23	4	8	12	1.51
24	4	6	10	1.26
25	6	2	8	1.01
26	4	2	6	0.75

Table 2-Age distribution of the population

Results:

Prevalence of the included canines

Of the 792 panoramic X-rays studied, 18 presented impacted canines representing 2.27% of the x-rays studied. Of the patients with impacted teeth, 8 are male patients and 10 are females.

Distribution of diagnostic of impacted maxillary canines according to age

Age of patient	Number of impacted Canines
13	0
14	3
15	2
16	2
17	0
18	2
19	3
20	3
21	0
22	0
23	1
24	0
25	0
26	2

Table 3- Age distribution of patients with diagnosed impacted canines

Distributions of incisors are affected by the impacted canines. We then analyzed the panoramic radiographs to see if the lateral incisors appeared to be impacted by the impacted canines.

We thus found 8 lateral incisors affected by the inclusion of the canines.

	Number of impacted canines	Number of affected incisors
Males	8	4
Females	10	4

Table 4 -Distribution of cases with implication of the lateral incisors

We searched for the position of the apex of the included canines to determine if it was in the eruption axis, or if it was more distally, at the level of the first or second premolar.

Position of the apex	Number of teeth
Normal eruption axis	10
At the level of first bicuspid	5
At the level of second bicuspid	3

Table 5 -Distribution according to the position of the apex

On X-rays with impacted canines, the angulation of these canines in relation to the middle line was studied, more precisely between the long axis of the canine and the middle line.

The middle line was defined on X-rays as the line passing through the intermaxillary suture, the anterior nasal spine and the nasal septum.

The impacted canines were divided into 3 groups according to their angulation.

- Group A: includes impacted canines with an angulation of 0 and 30 degrees from the midline
- Group B: includes the impacted canines having an angulation of between 30 and 60 degrees in respect to the middle line
- Group C: includes the impacted canines having an angulation of between 60 and 90 degrees in respect to the middle line

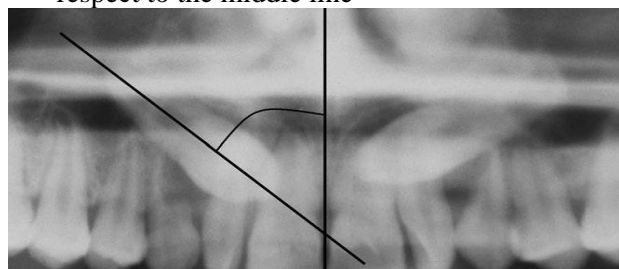


Fig. 1- Example of angulation measurement of impacted canines in respect to the midline

	Group A	Group B	Group C
Number of teeth	14	3	1
males	6	2	0
females	8	1	1

Table 6 -Distribution according to the angulation of the impacted canines

	Right quadrant	Left quadrant
Males	6	2
Females	2	8
Total	8	10

Table 7 -Distribution of the canines included according to the quadrant

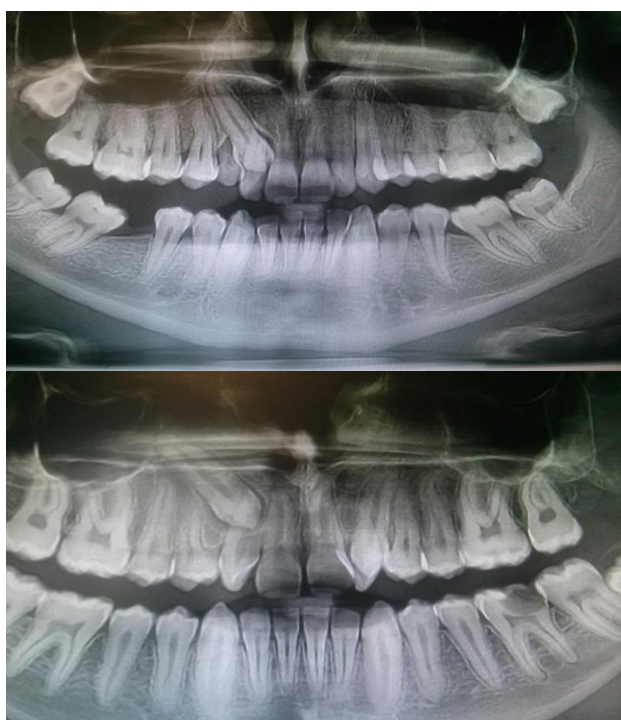

Fig.2- Examples of panoramic X-rays used for canine impaction screening

Discussions:

The use of panoramic X-rays in the screening of the included canines is a method found in many studies on the included canines, which even if it does not have reliability and a perfect precision remains a method of choice because of its ease of realization.

Panoramic X-ray is a widely used method. Although sometimes patients have distortions in the frontal dento-alveolar area, it has been shown that panoramic radiographs can be

reliable for geometric measurements in the clinic.

Vertical linear measurements, ratio calculation and angle measurement can be done on a panoramic X-ray precisely and accurately. In addition, it is an indicator for determining the bucco-palatal position of the impacted canines [20].

Some studies tend to show that CT / CBCT represent an alternative of choice in the impacted canine research.

This allows in particular:

- superior evaluation of the apical region of the canine
- better identification of resorption of adjacent teeth
- more precise evaluation of the position of the canine in relation to the dental arch and adjacent structures.

A study on the prevalence of impacted canines performed on a Cypriot population had chosen a age range for patients between 14 and 20 years [9]. Another study on the prevalence of lateral incisor hypodontia and the impaction of canine in the Cypriot population had chosen an age range for patients between 13 and 22 years of age.

This is to prove that the chosen age range for our study is comparable to other studies dealing with the subject.

The inclusion of teeth is a common phenomenon, frequently encountered in dental practice. An orthopantomographic study of 4065 people showed that 14.1% of people had a dental inclusion [1].

The impacted canines are the second teeth most affected by impaction after the third molars according to the vast majority of studies. However, a study of Vergopoulos in patients at the Mainz Dental Institute found that canines were the most commonly impacted teeth [16].

Several studies on canines have calculated the incidence of their impaction in the maxillary and their specificities.

-A study of 7089 cases studied from patient charts and x-rays found an incidence of 0.8% of the impacted canines, with the highest incidence in the 12 to 20 age group [14].

- A study in Turkey on 4,500 people had an incidence of 3.29% of maxillary canines impaction. [24].

- Another study also done in Turkey showed an incidence of maxillary canines impaction of 2.9%. [24]

- Another study carried out among the Cypriot population obtained 3.53% of canine impaction [9]

-A study in a population of children and adolescents in South China found an incidence of 2.1%. [21]

- A study performed on Hungarian patients showed a prevalence of maxillary canines impaction of 5.4%. [14]

In our study we found an incidence of 2.27% of the impacted canines, which is a result that is rather average when compared to the other results above.

We also looked for the prevalence of impacted canines in men and women and obtained 44.4% for men and 55.5% for women. As in other studies, we found a higher percentage of impacted canines in women:

-In the study conducted by Rhorer the distribution of canine impaction was 71.9% in women against 28.8% in men [16]

-In the study by Ake Nordenram and Christian the distribution was 61.2% for women and 35.8% for men. [16]

-In Sjanani and King's study it was shown that women were 1.5 times more likely to be affected than men. [21]

It has been suggested that the high frequency of canines included in women would be due to a smaller skull which would lead to a decrease in the skeleton of the face and jaws. This would increase the risk of inclusion of canines. It has also been suggested that the higher prevalence of canines in women than in men may be related to a higher incidence of lateral incisors agenesis or microdontia [21].

We only found 1 case out of 18 of bilateral impacted canines. Our result therefore differs from the other studies with which we compared our results.

-What to Rhorer where it was found 14% of canine impaction bilaterally.

-Created in children in southern China, 17.1% of impacted maxillary canines were bilaterally [21]

-Another study found that in 20.49% of cases patients had more than one impacted canine [2]

-Finally Nordenram and Stromberg found bilaterally impacted canines in one third of patients. [16]

We found 44.4% impacted canines on the right and 55.5% on the left. Studies seem to show varied results on this characteristic.

-Rhorer found in his study that the occurrence of the impacted canines was greater in the left quadrant than in the right with a ratio of 50/36, the remaining 14% being bilateral [21]

-In the Nordenram and Stromberg study, the ratio between the right and left quadrants is 52/48. [16]

-In another study on the use of the X-ray panoramic radio to determine the position of maxillary impacted canines, it was found on 130 impacted canines that 67 were on the right and 62 on the left, a ratio of 51.5 /48.5 [10].

Transmigration of the maxillary canines is a known anomaly with an incidence of 0.13% for the maxillary canines and 0.18% for the mandibular canines, according to the results reported by Aydin and Al and 0.05% for the maxillary canines. and 0.22% for mandibular canines according to Celikoglu, Kamak and Oktay. [3]

Transmigration is defined as an enclosed tooth that has crossed the middle line. On more than half of its length or according to another definition a pre-eruptive migration of a tooth through the middle line.

The etiology and exact mechanisms of canine transmigration are not yet clear, although a number of factors have been advanced. The rarity of transmigrated maxillary canines could be attributed to the small distance between the roots of the maxillary incisors and the floor of the nasal fossae as well as the root width of the maxillary incisors which could block transmigration [14].

In our study no transmigration of maxillary canines was observed. This could be explained by the small number of impacted canines studied and the low incidence of this phenomenon in the maxilla.

We also observed the impact of the enclosed canines on the adjacent teeth and the number of lateral incisors that appeared to be affected by the inclusion of the canines. We found that eight incisors among the 18 cases appeared to be affected.

The resorption of the maxillary lateral incisor caused by maxillary included canines is

a common phenomenon. Root resorption is difficult to treat and usually leads to extraction of the tooth.

We also studied the angulation of the included canines in relation to the middle line. 14 out of nine 18 had angulation between 0 and 30 ° from the midline.

Numerous studies have also focused on the palatal or labial position of the impacted canines.

-A study gives a prevalence of 15% of canines impacted in labial position and 85% of canines in palatine position. [17]

-Other authors have shown that the canine is impacted in palatine position in 70 to 85% of cases.

If the impacted teeth with a labial position erupt, they do so vertically, buccal and in a higher position.

On the other hand, palatal teeth, due to the density of palatal bone, finer palatal mucosa and a more horizontal position, rarely erupt without orthodontic treatment.

Conclusions:

Our study found a prevalence of maxillary impacted canines in the average of the studies found in the literature on the subject. It has also been confirmed in this study that this phenomenon affects women more than men.

The impacted canines were mostly unilateral, with a higher number at the left quadrant. The rare phenomenon of maxillary transmigration was not observed, but several lateral incisors appeared to be affected by the included canines.

This study shows that the impaction of the canine is a phenomenon also common in the Romanian population and can have serious consequences on surrounding structures if not treated early.

This shows the importance of early diagnosis in the dental office so that adequate follow-up and treatment can be put in place at the best time.

Acknowledgment: All authors are considered to have equal contribution in the development of this study and writing of the article.

Bibliography:

- [1] Aitasalo K, Lehtinen R, Oksala E. An orthopantomographic study of prevalence of impacted teeth. *Int J. oral Surg.* 1972;1:117-120
- [2] Boisramé-Gastrin S., Denhez F. Extractions des canines et autres dents incluses. EMC (Elsevier Masson SAS,Paris), Stomatologie, 22-096-A-10,2011
- [3] Celikoglu M, Kamak H. Oktay H. Investigation of Transmigrated and Impacted Maxillary and Mandibular Canine Teeth in an Orthodontic Patient Population. *J Oral Maxillofac Surg.*2010 ; 68:1001-1006
- [4] Delsov L, V. Orti, M. Chouvin, P. Canal. Canines et incisives maxillaires incluses: diagnostic et thérapeutiques. EMC-Orthopédie dentofaciale 2006:1-17 [Article 23-492-A-11].
- [5] Favre de Thierrens C, Moulis C, Bigorre M, De La Chaise S. Inclusion dentaire (I) Aspects biologiques, odontogénétiques, physiologiques et pathologiques. *Encycl Méd Chir, Stomatologie, 22-032-A-15, Odontologie, 23-400-A-16, 2003, 10p.*
- [6] Freisfeld M, Arne Dahl I, Jager A, Drescher D, Schuller H. X-Ray Diagnosis of Impacted Upper Canines in Panoramic Radiographs and Computed Tomographs. *J Orofac Orthop/Fortschr Kleferorthop.* 1999; 60: 177-84(Nr.3)
- [7] Goldberg M, Gaucher C. Embryologie de la dent. EMC – Stomatologie 2013;8(2):1-21 [Article 22-001-A-22].
- [8] Jacobs S. The impacted maxillary canine. Further observations on aetiology, radiographic localization, prevention/interception of impaction, and when to suspect impaction. *Australian Dental Journal* 1996; 41:(5):310-6
- [9] Kamiloglu B, Kelahmet U. Prevalence of impacted and transmigrated canine teeth in a Cypriote orthodontic population in the Northern Cyprus area. *BMC Research Notes* 2014, 7:346
- [10] Katnelson A, Flick W, Susarla S, Tartakovsky J, Miloro M. Use of Panoramic X-RAY to Determine Position of Impacted Maxillary Canines. *J Oral Maxillofac Surg* 68:996-1000, 2010

- [11] Korbendau JM, Pajoni D. Canines maxillaires, inclusion profondes, diagnostic: choix du protocole opératoire. *J Parodontol Implantol Orale* 2000;19:279-89
- [12] Kuftinec MM, Stom D, Shapira Y. The impacted maxillary canine : a review of concepts. *ASDC J Dent Child* 1995;62:317-24
- [13] Langlade M. *Thérapeutique orthodontique*. Paris: Maloine; 1986 (863p).
- [14] Liu D, Zhang WL, Zhang ZY, Wu YT, Ma XC. Localization of impacted maxillary canines and observation of adjacent incisor resorption with cone-beam computed tomography. *Oral Surg Oral Med Oral Pathol Oral Radio Endod* 2008;105:91-8
- [15] Moreira T, Braga A, Ferreira A. Prevalence of Palatally Impacted Canines. *International Journal of Dental Science and Research* 3. 2016; 2-8
- [16] Nordenram A, Stromberg Christian. Positional variations of the impacted upper canine. *O.S., O.M.& O.P.* December, 1966; 22(6)
- [17] Richardson G, Russell K. A Review of Impacted Permanent Maxillary Cuspids – Diagnosis and Prevention. *J Can Dent Assoc* 2000; 66:497-501
- [18] Romerowski J, Bresson G. Formes et fonctions de la dent. *EMC – Chirurgie orale et maxillo-faciale*. 2015;10(1):1-22[Article 22-003-A-05]
- [19] Romerowski J, Bresson G. Morphologie dentaire de l'adulte: canines. *EMC – Chirurgie orale et maxillo-facile* 2012;1-8 [Article 22-003-A-11].
- [20] Sajnani A, King N, Early prediction of maxillary from panoramic radiographs. *Am J Orthod Dentofacial Orthop* 2012;142:45-51
- [21] Sajnani A, King N. Prevalence and characteristics of impacted maxillary canines in southern Chinese children and adolescents. *Journal of Investigative and Clinical Dentistry* (2014), 5, 38–44
- [22] Strbac G, Foltin A, Gahleitner A, Bantleon HP, Watzek G, Bernhart T. The prevalence of root resorption of maxillary incisors caused by impacted maxillary canines. *Clin Oral Invest.* 2013;17:553-564
- [23] Tilotta F, Folliguet M, Séguier S. *Physiopathologie de l'éruption dentaire*. *EMC-Stomatologie* 2014; 9(1):1-8 [Article 22-030-A-10].
- [24] Wrledt S, Jaklin J, Al-Nawas B, Wehrbein H. Impacted upper canines: examination and treatment proposal based on 3D versus 2D diagnosis. *J Orofac Orthop* 2011;73:28-40