



5th International Conference
"Computational Mechanics and Virtual Engineering"
COMEC 2013
24- 25 October 2013, Braşov, Romania

FRACTAL DIMENSION OF CHROMATIN REGIONS IN HISTOLOGICAL PICTURES REVEALS THE PRESENCE OF EPITHELIAL TUMOURS

Liviu GAIŢĂ¹, Manuella MILITARU¹, Gabriela POPESCU¹

University of Agronomic Sciences and Veterinary Medicine of Bucharest, Romania, clinica@ortovet.ro

Abstract: *This study examines the hypothesis that the fractal dimension of chromatin regions in histological pictures has a systematic and measurable variation when tumors emerge in a tissue. We used 194 histological pictures of healthy tissue and of tissue of the same nature with tumoral changes from 24 cases of dogs and cats treated for malignant and benign epithelial tumors: carcinoma, seminoma, adenoma, trichoblastoma, epitelioma. Fractal analysis was performed on pictures reduced to selected chromatin areas. Results indicate that for chromatin pictures at x40 magnification the fractal dimension is significantly increased when tumoral changes are present on more than 20% of the picture area. The largest effect on fractal dimension was identified for mammary gland carcinoma.*

Keywords: *pathology, fractal analysis, histology, oncology*

1. INTRODUCTION

In spite of huge progress made lately in laboratory and information technology, there are parts of the pathology practical work that are still entirely dependent on the heavy involvement of the human expert. The histopathologic diagnostic is an example: the microscopic images of tissue from the suspected lesion are examined thoroughly, many of the cell and tissue architecture features are assessed against classification criteria, and a conclusion is drawn on the status of a normal or pathologic state, on the type, and on the severity of the lesion – when that is confirmed. This work is done by a highly qualified expert, hence the inherent subjectivity and vulnerability to errors is unfortunately combined with the responsibility derived from the formulated diagnostic and with the pressure of time, which rarely allows for second or third opinions, as therapy needs to start or be adjusted as soon as possible.

One of the tools identified as a possible contribution to alleviating this constraint is fractal analysis applied on the histological pictures captured with a digital camera. The basis for this approach is the fractal aspect of biological objects, which was revealed by Mandelbrot himself [1], and stands out in an obvious manner in most various circumstances and over several scale sizes. It has been confirmed [2] in macroscopic and microscopic morphology of organisms (as highlighted by various imagistic techniques), in the dynamics of physiological parameters, in DNA sequences, in population dynamics. The potential usefulness of fractal analysis for diagnostic purposes was advocated as early as 1997 by Cross [3] as the fractal dimension seems to be systematically impacted by the pathologic changes of morphology at cellular and tissular level. Einstein [4] brought extensive evidence of the capacity of fractal analysis to identify the changes that occur in the nuclear chromatin when pathologic processes occur; that paper outlined also some of the most effective ways in which the fractal dimension, as a synthetic numeric measure associated with characteristics of a lesion, can be integrated in heuristic or statistical models to facilitate diagnostic and prognostic.

A number of positive results were published, confirming the potential usefulness of the fractal analysis in diagnostic and prognostic, in various fields of human medicine [16]. A particular domain where fractal analysis is considered useful is oncology [6], [7]. The aim of this study was to check if the fractal dimension is useful for the identification of cancerous lesions in histology samples from dogs and cats. Only scarce relevant results were published for fractal analysis applied in the cito- and histo-pathology of these species. [8], [9], [10], [11].

2. MATERIALS AND METHODS

In studying the effectiveness of the fractal analysis as a pathology tool, an important constraint is the wide variability of the cases on which it is intended to be tested and applied. To simplify the problem and in hope of a clarification we selected cases of organs affected by epithelial tumours and organised the histology images in two groups:

Group 1, images in which morphology features indicative of cancer were present on more than 20% of the total area of the image;

Group 2, images in which morphology features indicative of cancer were absent, i.e. present on less than 20% of the total area of the image.

The morphology features indicative of cancer were the histology features revealed by H&E staining which are traditionally used to diagnose the tumours in dogs and cats according to WHO classification. Images in both groups were selected from the same patients, thus limiting the impact of factors other than the presence/absence of tumoral changes on the fractal dimension of the pictures. Briefly, the control group was made of pictures of healthy tissue of the same nature from the same patients.

We analysed samples from 24 patients, 19 dogs and 5 cats, with benign and malign epithelial tumours: mammary gland carcinoma, other carcinoma, mammary adenoma, epithelioma, seminoma, mammary fibroadenomatosis, mammary adenoma, trichoblastoma, trichoepitelioma, hemangiopericitoma. They received treatment at the ORTOVET clinic in Bucharest and the histology diagnostic was made in all cases in the Pathology Laboratory of the FMV-USAMV in Bucharest, between May 2011 and March 2012 [12]. The fractal analysis was performed on 194 images, 142 images in *Group 1* and 52 images in *Group 2*.

Digital images were captured on Olympus BX41 microscope with its built-in camera and with Olympus Cell^B software. Here we present results based on the set of pictures made with the x40 magnification objective.

The choice of method and parameters for image processing and for fractal analysis made use of outputs from previous research on optimising the procedure for a good sensitivity of the resulting fractal dimension to subtle changes in the examined tissue [13].

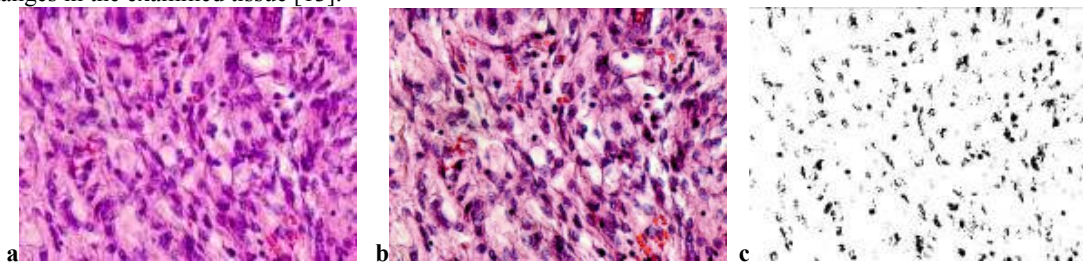


Figure 1: Picture processing: (a) original picture, (b) result of balance on hue, contrast, brightness, and saturation, followed by directional sharpen, (c) result of segmentation by colour mask to extract chromatin regions, followed by conversion to black and white

There were three major steps carried out in preparing the picture for the fractal analysis. (i) *The balance* of the picture, regarding hue, contrast, brightness and saturation. Directional sharpen was also applied. (ii) *The segmentation* of the picture. It was made by a colour mask that identified and selected the chromatin regions in the picture, the rest of the picture being deleted. (iii) Finally, *the conversion* of the picture – limited now to chromatin areas - to a grey palette. Once the parameters of the balance procedure and of the colour mask were chosen, the images were batch processed with Corel[®] PhotoPaint.

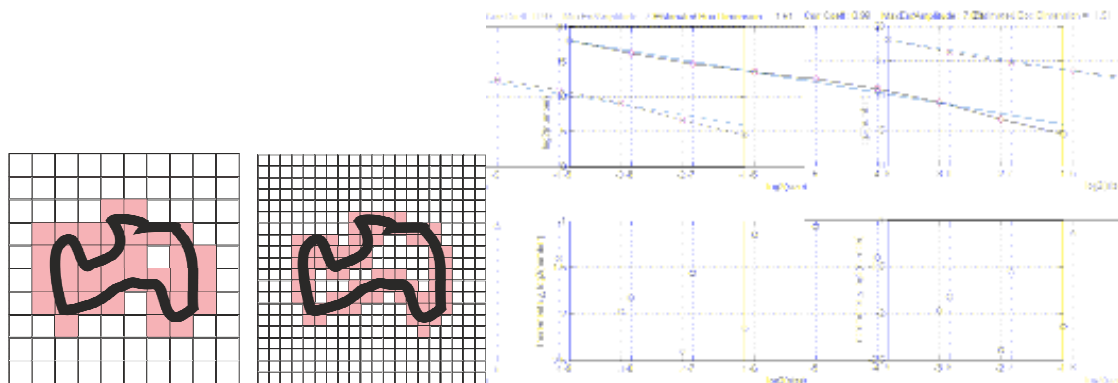


Figure 2: Computing the fractal dimension of an image by the box method, using FracLab

The fractal analysis of the gray-scale images was performed using FracLab 2.05, developed by Research Center INRIA Saclay - Île-de-France. The method chosen to compute the fractal dimension was the box method, with the regression curve drawn by the least squares method (**Figure 1**). The box method provides a very good approximation of the Hausdorff dimension [...]:

$$D_H = \lim_{\varepsilon \rightarrow 0} \frac{\log N(\varepsilon)}{\log \frac{1}{\varepsilon}} \quad (1)$$

The statistical analysis of the results was made using StatsDirect 2.7.9.

3. RESULTS AND DISCUSSION

The results in **Table 1** suggest that the fractal dimension of the chromatin regions is greater in the images where tumoral changes are present over more than 20% of the total area.

Table 1: Fractal dimension FD of chromatin regions
 Group 1: tumour lesions on less than 20% of the total image area
 Group 2: tumour lesions on more than 20% of the total image area

Group	Number of images in the group	Average FD	Standard deviation	CI 95% for average FD	Maximum FD	Minimum FD
Group 1	52	1.641981	0.026268	1.649294 ...1.634668	1.7083	1.592
Group 2	142	1.67831	0.040498	1.685029 ...1.671591	1.7685	1.5945

The Fisher test showed a significant difference between the variances in the normal and tumoral groups and the appropriate variant of the Student test was used. The resulting equivalent number of degrees of freedom for the considered population was 140.04762 and the value for $t=7.292236$. The probability that the difference between the averages of the groups is a random event, p is less than 0.0001. Mann-Whitney test confirmed the results. The statistical power for a 5% significance is over 99.99%. The confidence interval $\pm 95\%$ for the difference - 0.036329 between the averages of the two groups is [-0.046155, -0.026503]. The 95% confidence intervals of the averages of the two groups are not overlapping (**Figure 3**).

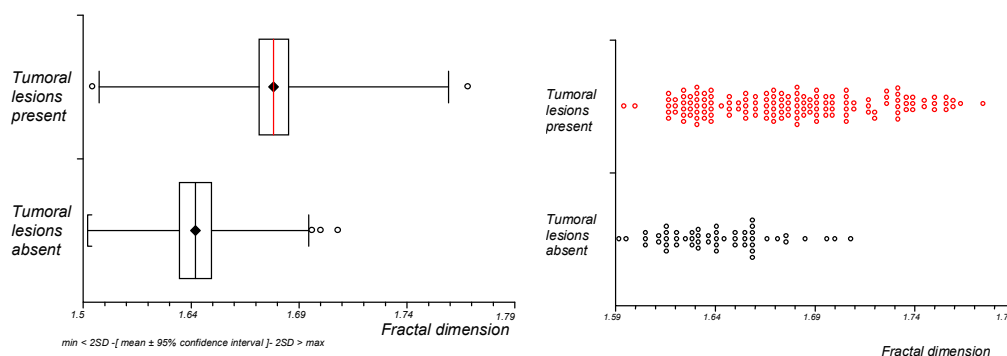


Figure 3: Spread and box-and-whisker plots for the fractal dimension: the $\pm 95\%$ confidence intervals when tumours are absent and, respectively present, do not overlap

On the subset of cases of mammary gland carcinoma, the gap increased between the 95% confidence intervals of the average fractal dimension in the presence, respectively absence of tumoral lesions. The statistical significance of the difference between the means was also greater, as the variances were similar, hence the standard Student test was acceptable.

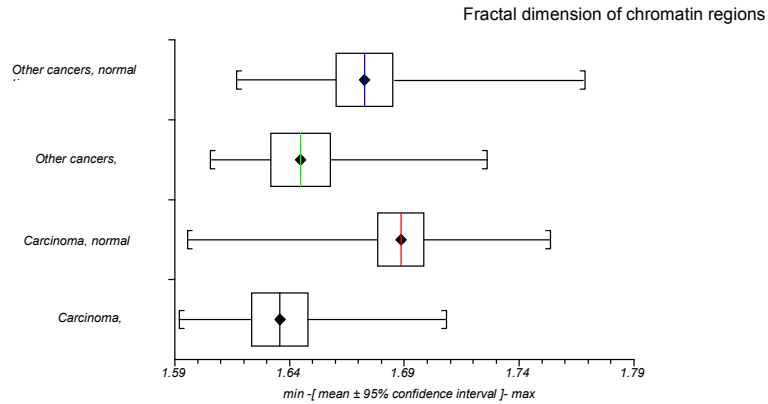


Figure 4: Fractal dimension of chromatin regions in normal/tumoral tissue for patients with mammary gland carcinoma and for patients with other types of cancer

The fact that the 95% confidence intervals of the averages of the two groups are not overlapping sustains the possibility to define distinct domains for the values of the fractal dimension that can be associated with the presence and, respectively, the absence of tumoral lesions in the histology image that is analysed.

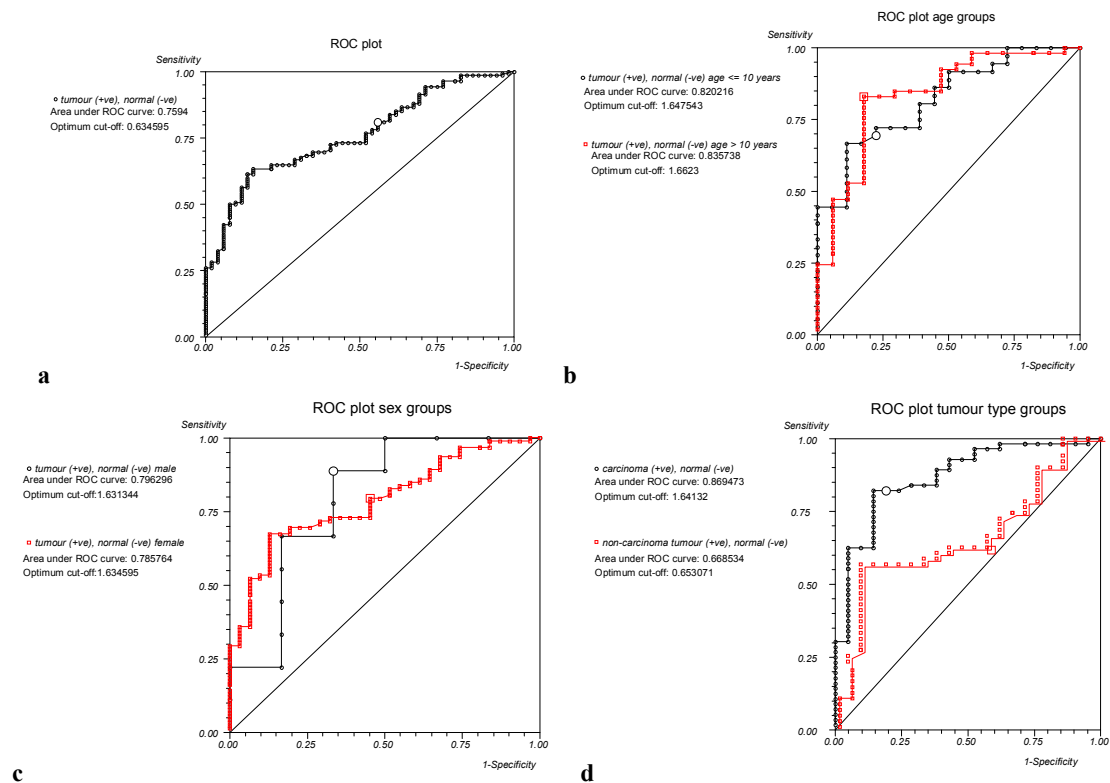


Figure 5: ROC plots for (a) the entire group studied, (b) separate age groups, (c) separate sex groups, and (d) separate tumour type groups

A ROC curve analysis was performed to illustrate and assess this possibility (Figure 5). The same analysis was repeated also for divisions into sex groups and age groups. Looking at the area under the ROC curve [17], it is remarkable that those divisions improved, especially the age division, the relevance of the fractal dimension as an indicator for the presence of tumours, in spite of the reduced size of data set for each group. It suggests that future research that could aim at defining normal and pathological domains for the fractal dimension should consider defining such domains separately for groups segregated by relevant criteria (age and sex among them).

The results presented here show that the correlation between the fractal dimension and the presence of lesions is strong enough so that the required sample size for a relevant statistical conclusion is attainable with reasonable effort.

Another possible approach to make use of the added value of the fractal dimension as a diagnostic tool is to directly corroborate it with other clinical, paraclinical, and therapeutic data in integrated models like artificial neural networks applied for diagnostic and prognostic.

4. CONCLUSIONS

Fractal dimension of chromatin regions in histological pictures varies systematically when epithelial tumour lesions occur, hence it can be used as a diagnostic tool. For some types of cancer, like the mammary gland carcinoma, there are indications that normal and pathological ranges could be defined for the fractal dimension of chromatin areas computed in standardised conditions. Using segregating relevant criteria like age and sex can improve the sensitivity and selectivity of this potential diagnostic instrument.

REFERENCES

- [1] Mandelbrot B., *The fractal geometry of the nature*, Freeman, San Francisco, 1993
- [2] Losa G. A., *The fractal geometry of life*, *Rivista di biologia*, Vol 102 (1), pp. 29-59, 2009
- [3] Cross S. S., *Fractals in Pathology*, *Journal of Pathology*, Vol. 182, pp.1-8, 1997
- [4] Einstein A. J., Wu H.-S., Sanchez M., Gil J., *Fractal characterization of chromatin appearance for diagnosis in breast cytology*, *The Journal of Pathology*, Vol. 185:4, pp. 366-381, 1998
- [5] Losa G. A., *Do complex cell structures share a fractal-like organization?*, 6eme Congres Europeen de Science des Systemes, Paris, 2005
- [6] Baish J. W., Jain R. K., *Fractals and cancer*, *Cancer Research*, Vol. 60, pp. 3683-3688, 2000
- [7] Amuda P.F. F., Gatti M., Junior F. N. F., Amuda J. G. F., Moreira R. D., Junior L. O., Arruda L. F., Godoy M. F., *Quantification of fractal dimension and Shannon's entropy in histological diagnosis of prostate cancer*, *BMC Clinical Pathology*, 13:6, 2013
- [8] De Vico G., Cataldi M., Maiolino M., Beltraminelli S., Losa G. A., *Fractal analysis of canine trichoblastoma*, *Fractals in Biology and Medicine*, Birkhauser Basel, 2005
- [9] De Vico, Peretti V., Losa G. A., *Fractal organization of feline oocyte cytoplasm*, *European Journal of Histochemistry* Vol. 49 (2), pp. 151, 2005
- [10] Simeonov R., *Computer-assisted fractal analysis of spontaneous canine mammary gland tumours on cytologic smears*, *Trakia Journal of Sciences*, Vol. 5(1), pp.65-88, 2007
- [11] Simeonov R., Simeonov G., *Nuclear cytomorphometry in feline mammary gland epithelial tumours*, *Veterinary Journal*, 179 (2): 296-300, February 2009
- [12] Popescu G., *Computer assisted morphometry and fractal analysis – complementary methods for the diagnostic and prognostic of epithelial tumours*, DVM dissertation guided by Prof. Militaru M., UASVM-FVM, Bucharest, 2012
- [13] Gaiță L., Militaru M., *Performance optimization of fractal analysis used for the microscopic pathology diagnostic*, *Scientific Research Contributions to Veterinary Medicine Advance*, Symposium, UASVM-FVM, Bucharest, 2011
- [14] Gaiță L., Militaru M., *Fractal Analysis Used for Identifying the Impact of Drugs on Hepatic Tissue*, *Journal of Comparative Pathology*, Vol. 148, Issue 1, January 2013
- [15] Gaiță L., Militaru M., *Current situation in using fractal analysis for tumour diagnostic and prognostic*, *Rev. Rom. Med. Vet.* 3/2010
- [16] Klonowski W., Stepien R., Stepien P., *Simple fractal method of assessment of histological images for application in medical diagnostics*, *Nonlinear Biomedical Physics*, 2010, 4:7
- [17] Zweig M. H., Campbell G., *Receiver-operating characteristic (ROC) plots: a fundamental evaluation tool in clinical medicine*, *Clinical Chemistry*, Vol. 39:4, pp. 561-77, 1993